

DOI: 10.21767/2254-6081.1000119

Premenopausal Patient with a Large (7 cm) Breast Cancer

Francesco Recchia

Ospedale Civile di Avezzano, Unità operativa di Oncologia, Italy

Corresponding author: Francesco Recchia, Ospedale Civile di Avezzano, Unità operativa di Oncologia, Italy, Tel: +39 863 52119; E-mail: frecchia1946@libero.it

Received: 12 December 2016; **Accepted:** 15 December 2016; **Published:** 19 December 2016

Citation: Recchia F. Premenopausal Patient with a Large (7 cm) Breast Cancer. Arch Can Res. 2016, 4: 4.

Case Blog

37 years old pre-menopausal patient with a large (7 cm) breast cancer (fnab: ER-, PGR-, KI 67, 70%, Cerb-2) (**Figures 1 and 2**).

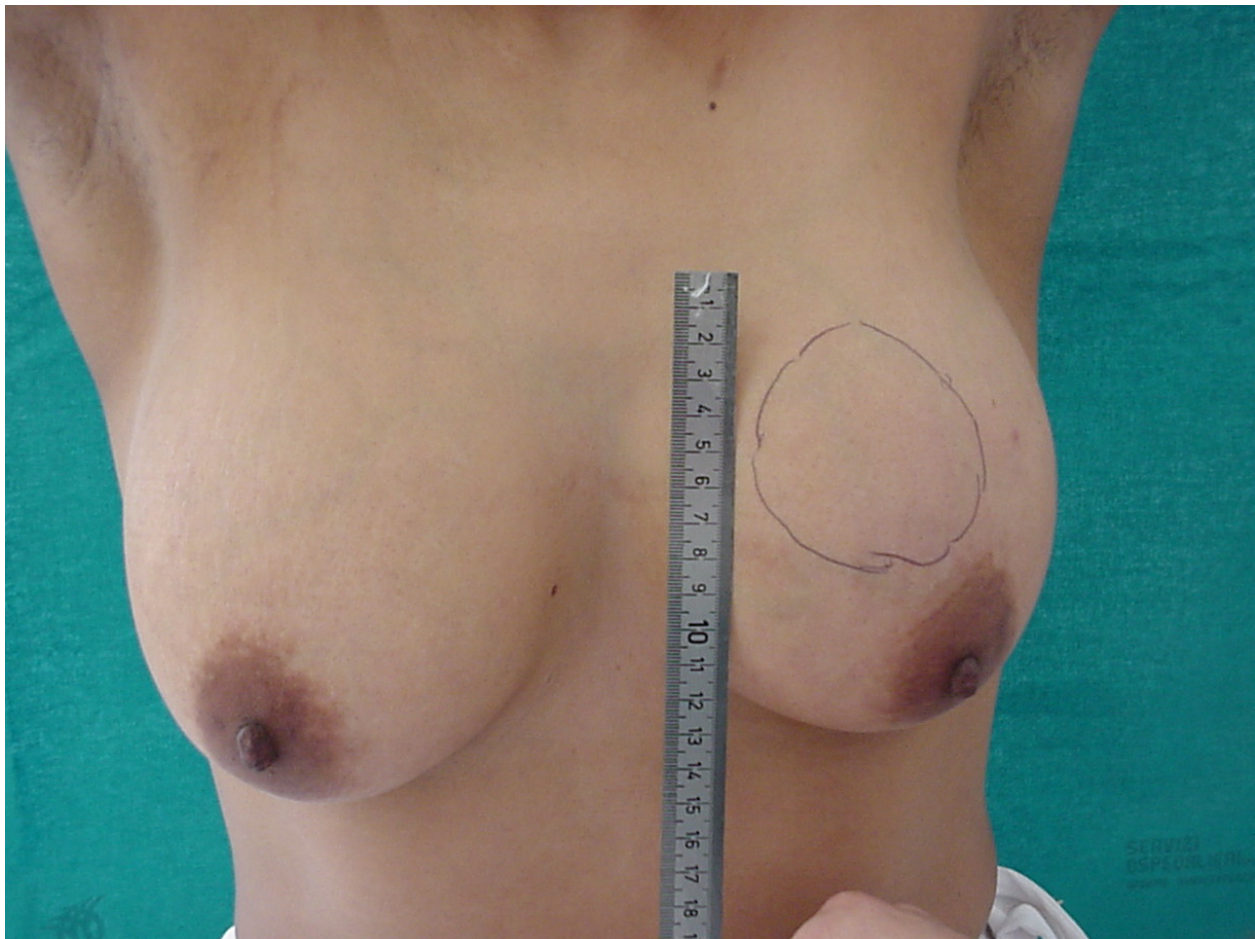


Figure 1 Patient before chemotherapy.

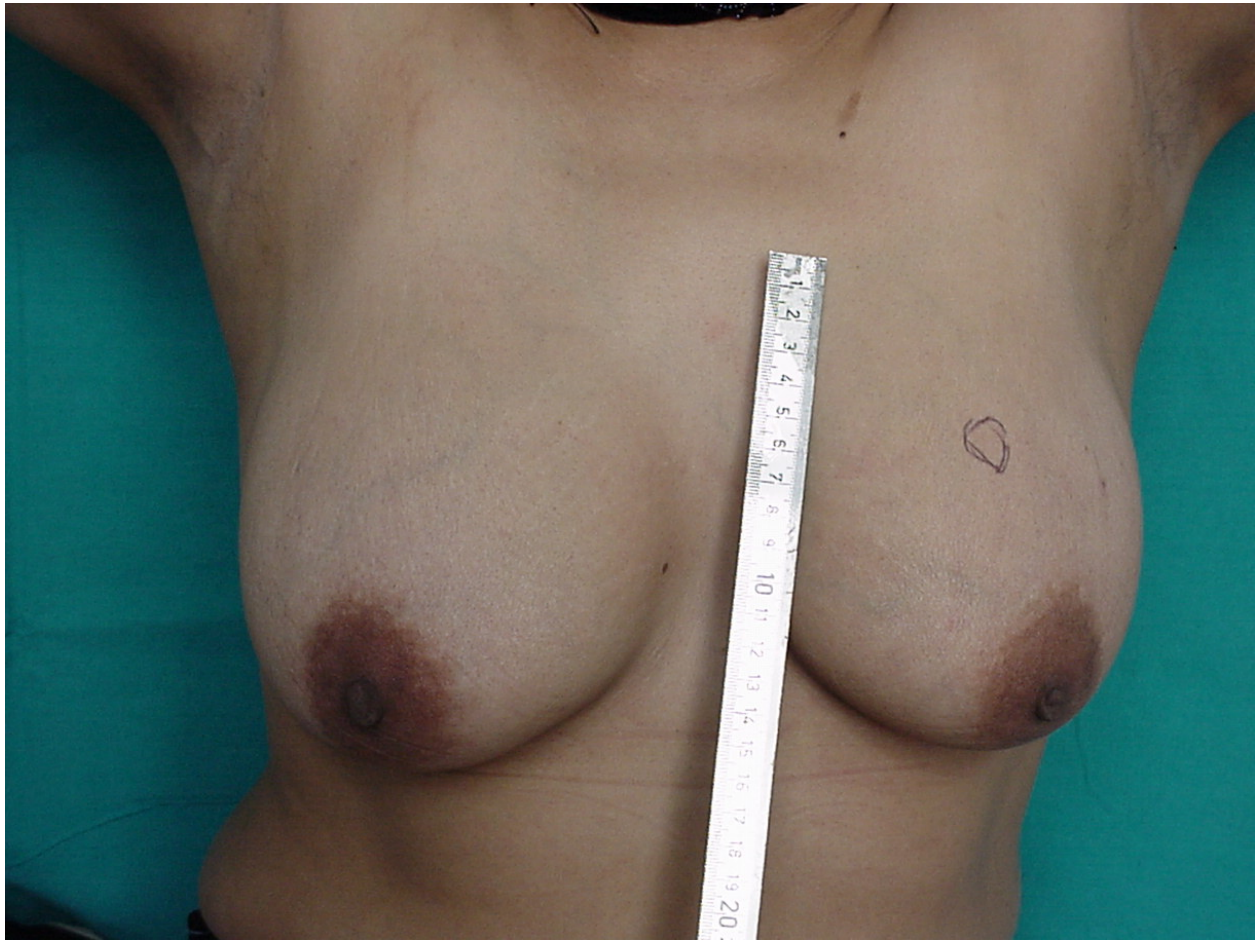


Figure 2 Patient after 2 cycles of chemotherapy.

- A) Photograph taken 1-10-2008.
- B) LH-RH analogue every 4 weeks followed by 3 courses of dose-dense chemotherapy every two weeks with G-CSF (CYCLOPHOSPHAMIDE 900 MG, MYOCET 70 MG, DOCETAXEL 120 MG).
- C) Photograph taken 17-11-2008.
- d) 03-12-2008: Quadrantectomy. Pathological complete response.
- e) Patient is disease-free after having received 3 more courses of (CMF with radiation therapy) and 8 years of follow-up.