

Horner's Syndrome and Syncope

Gustav Y Cederquist¹ and James J Harding^{1,2}

¹Department of Medicine, Memorial Sloan Kettering Cancer Center, 300 East 66th Street, NY, NY 10065, USA

²Department of Medicine, Weill Cornell Medical College, 1300 York Avenue, NY, NY, 10065, USA

Corresponding author: James J Harding, Department of Medicine, Memorial Sloan Kettering Cancer Center, 300 East 66th Street, NY, NY 10065, USA, Tel: 646-888-4314, E-mail: Hardinj1@mskcc.org

Received: 08 July 2016; **Accepted:** 11 July 2016; **Published:** 14 July 2016

Citation: Cederquist GY, Harding JJ. Horner's Syndrome and Syncope. Arch Can Res. 2016, 4: 3.

Case Blog

A 70-year-old female complained left eyelid drooping and three syncopal episodes over one week. Six years prior, she was diagnosed with Merkel cell carcinoma of the right nasal vestibule and underwent combined modality therapy. Physical examination revealed left-sided ptosis and miosis (**Figure 1A**). Computed tomographic imaging revealed supraclavicular and thoracic inlet adenopathy. A lymph node encased the left common carotid artery (**Figures 1B** and **Figure 1C**, red arrow) leading to compression of second-order sympathetic neurons and Horner's Syndrome. Right-sided cervical adenopathy along the carotid artery stimulated the carotid baroreflex leading to recurrent syncope (**Figure 1C**, red circle). Horner's syndrome is the triad of miosis, ptosis, and anhidrosis. The latter occurs in 50% of cases, is subtle, and depends on level sympathetic disruption. Horner's syndrome should prompt an evaluation for lesions along the sympathetic tract, including stroke, malignancy, and carotid artery dissection. The patient received etoposide and carboplatin with transient symptom improvement.

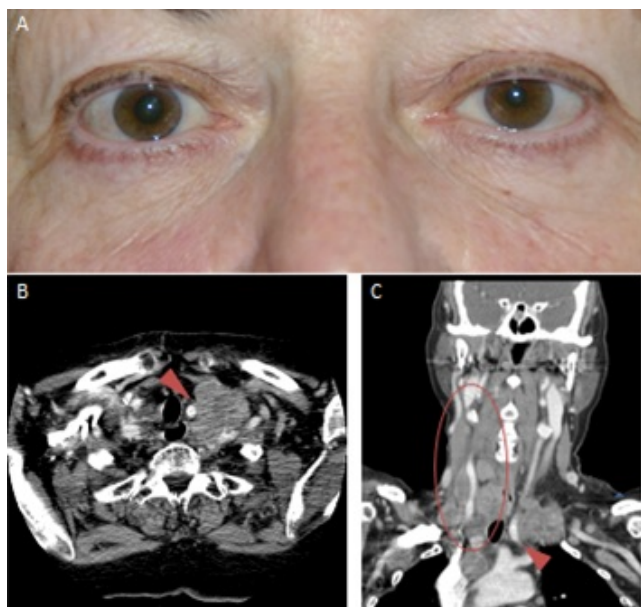


Figure 1 Second-order sympathetic neurons and Horner's syndrome.